ARRANGEMENT OF ARTIFICIAL TEETH

It is the setting or placement of an artificial teeth on the trail denture. The arrangement of teeth achieved after fixing the record bases on the articulator by mounting.

Guiding lines aid in arrangement of artificial teeth

For Maxillary Cast

1. A line drawn parallel to the frontal plane and touches the anterior margin of incisive papilla, aid in the positioning of the upper *central* incisors.
2. The mid line follows the mid palatal suture and bisects the incisive papilla; this line is perpendicular to the line drawn before.
3. The canine eminence line marked on the cast if can be notice.

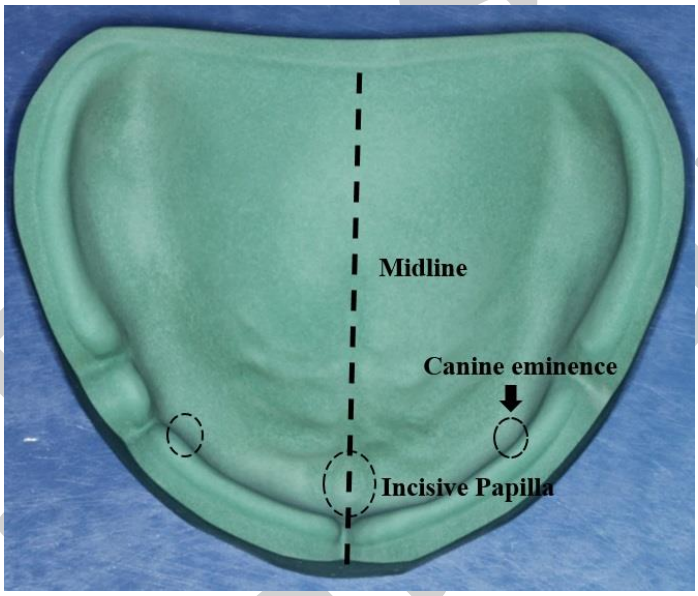

Guide lines of the maxillary cast

For Mandibular Cast

1- A line is drawn parallel to the frontal plane bisecting the residual ridge, aid in the positioning of the mandibular *central* incisors.
2- A point designates the distal of mandibular canines.
3- A line follow the crest of the residual ridge extended from the canine point to the middle of retro molar pad, aids in the bucco-lingual position of the mandibular posterior teeth.
4- A line that bisects the vertical height of the retromolar pad aids in the establishing the vertical position of the occlusal surfaces of the posterior teeth. (Figure below shown these lines)

Dr. Firas A. Farhan

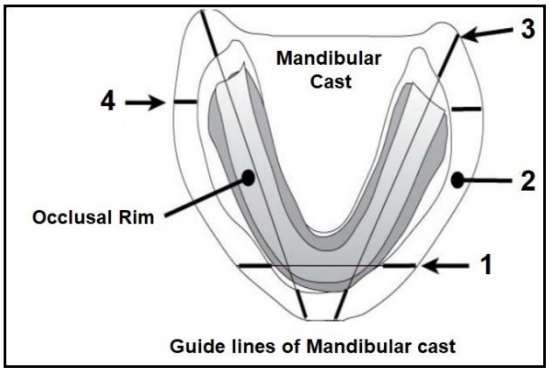

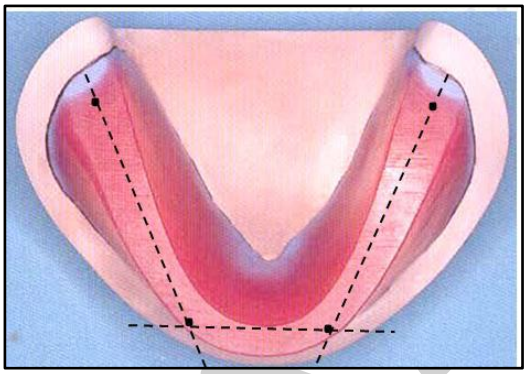

Arrangement of Anterior Teeth

The anterior teeth should be arranged to provide the following requirements:

1. Proper lip support.
2. Satisfactory phonetics.
3. Pleasing esthetics.

A. Arrangement of the Maxillary Anterior Teeth:

1. Maxillary Central Incisors

- **In frontal view:** the contact point between right and left central incisors should coincide with the mid-line of cast. The incisal edge of each one should touch the occlusal plane. The long axis is perpendicular to the occlusal plane.
- **In sagittal view:** should have slight labial inclination (5 degrees).
- **In occlusal view (horizontal plane):** the two central incisors should be placed to give the beginning of the curvature of the arch; generally, the labial surfaces of central incisor located at distance of 8-10 mm from the center of incisive papilla.

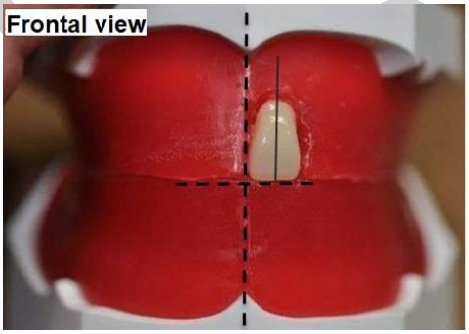

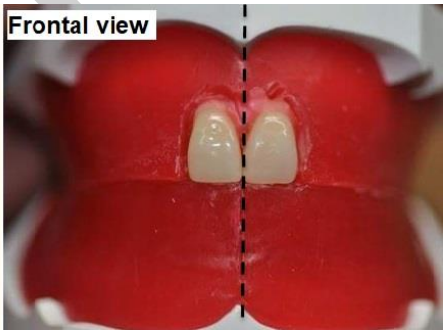



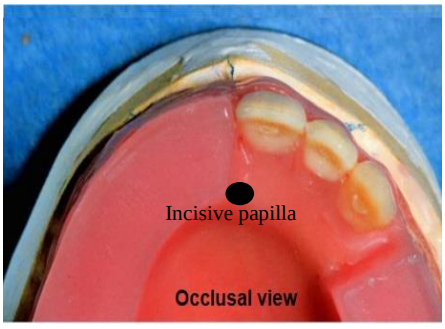

Dr. Firas Abdulameer Farhan

2. *Maxillary Lateral Incisor:*

- **In frontal view**, the incisal edge is 1-2 mm above the occlusal plane, and the long axis shows a little distal inclination.
- **In sagittal view**, the maxillary lateral incisor should have slight labial inclination (20 degrees).
- **In occlusal view**, the cervical area is depressed more than the central incisors, and the distal edge should be rotated lingually to form the arch curvature.

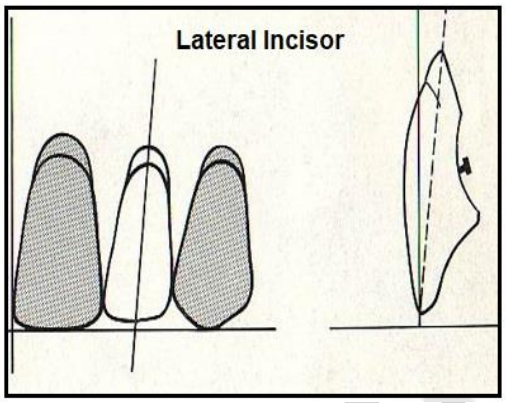

3. *Maxillary Canine:*

- **In frontal view**, the tip of the canine should touch the occlusal plane, and the long axis is perpendicular to the plane.
- **In sagittal view**, the long axis is vertical.
- **In occlusal view**, the cervical area is prominent. The maxillary canine represents the corner of the mouth, and the turning point of the maxillary arch, also it forms the transition from the anterior teeth to posterior teeth.

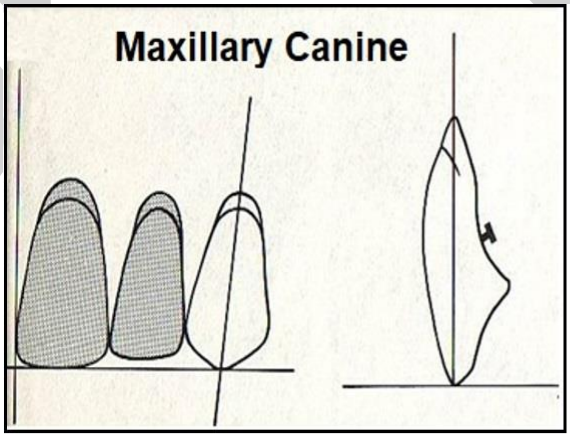

Dr. Firas Farhan

B. Arrangement of Mandibular Anterior Teeth:

1. Mandibular Central Incisor:

- **In frontal view**, the long axis is vertical. Their mid line should coincide with the maxillary mid line.
- **In sagittal view**, should have slight labial inclination.
- The incisal edge should have 2 mm of vertical overlap (overbite) and 2 mm of horizontal overlap (overjet), in respect to the maxillary central incisors.

Overbite (vertical overlap): It is the vertical extension of the upper anterior teeth over the lower teeth 2 mm in a ***Vertical Direction*** when the opposing posterior teeth are in contact in centric occlusion.

Overjet (horizontal overlap): It is the projection of maxillary anterior teeth beyond their antagonist 2 mm in a ***Horizontal Direction***.

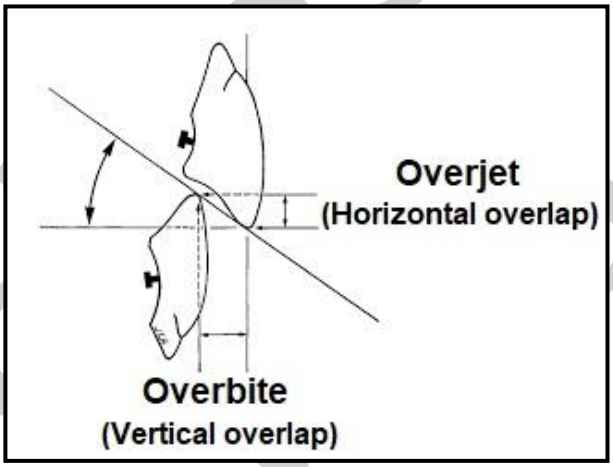

2. Mandibular Lateral Incisor:

- **In frontal view**, the long axis is vertical to the occlusal plane.
- **In sagittal view**, should have slight labial inclination.
- The incisal edge of the Mandibular Lateral incisors should be positioned behind the Maxillary Lateral incisor 2 mm (overbite) and 2mm (overjet). In horizontal view, the distal edge rotated towards lingually to have the arch curvature.

3. Mandibular canine:

- **In frontal view**, the long axis has slight distal inclination. The tip of lower canine should be place in the embrasure between maxillary lateral incisor and canine.
- **In sagittal view**, the long axis has slight lingual inclination.
- **In occlusal view**, the cervical area is prominent.
- The arrangement of anterior teeth should follow the form of the arch, which is either square or ovoid.

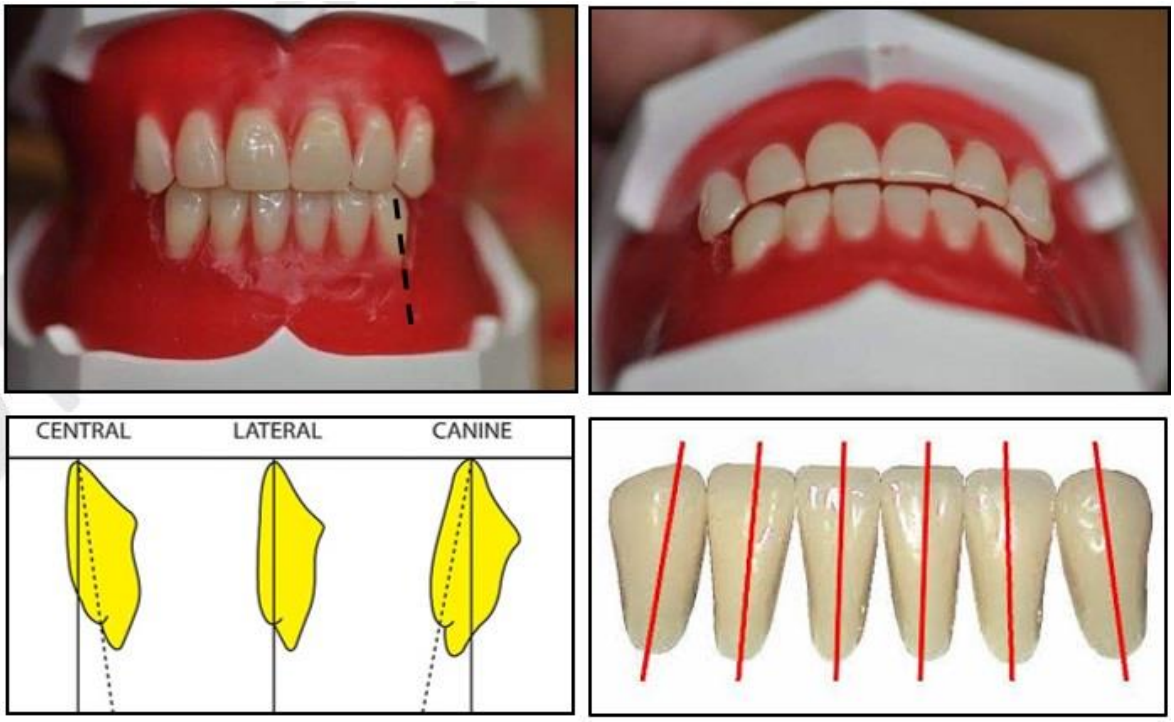

Dr. Firas Farhan